

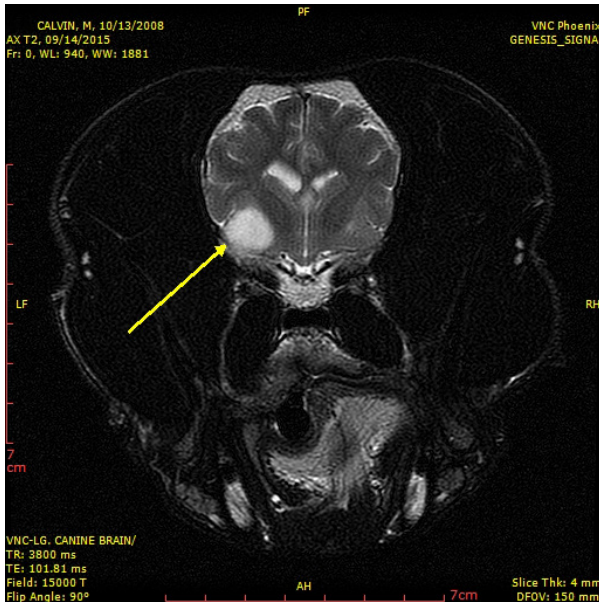IMAGE A: Pre-Treatment
September 14, 2015

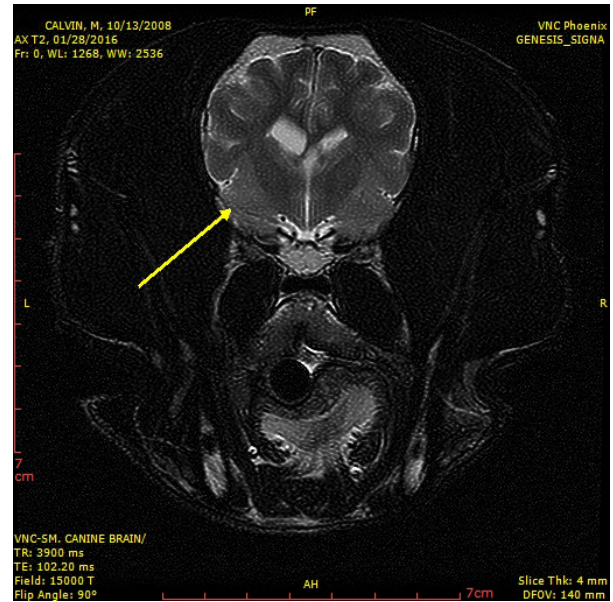


IMAGE B: Post-Treatment
January 28, 2016

PATIENT: Calvin, a 7-year-old male, neutered French Bulldog.

TUMOR HISTOLOGY: Glioma (suspected)

ANATOMIC LOCALIZATION: CNS - Brain

BACKGROUND: Presented with cluster seizures in September 2015, experiencing as many as 8-10 focal and grand mal seizures within a 24-hour time frame. MRI imaging revealed a well-demarcated 1.2 cm spherical tumor located in the left piriform lobe of the brain, suspected to be glioma (see Image A). Previous history was limited to severe upper airway disease (Brachycephalic Syndrome) with no prior history of seizure activity.

TREATMENT: Calvin's owners opted for stereotactic radiosurgery (SRS). Calvin was prescribed 27 Gy in 3 fractions of 9 Gy per fraction over the course of 3 days (September 2015). Total treatment time was 4.98 minutes per fraction. Calvin experienced one seizure episode following the first fraction, but tolerated the remainder of the procedure well. Post-treatment response was uneventful.

OUTCOME: Follow-up MRI images taken 120 days post treatment (January 28, 2016) revealed mild T2/FLAIR hyperintensity throughout the white matter of the left internal capsule and left periventricular region, however the mass (glioma) was not grossly evident (see Image B) and there were no regions of abnormal contrast enhancement. Upon physical exam, Calvin remained asymptomatic and demonstrated none of the neurologic deficits identified pre-treatment.

